



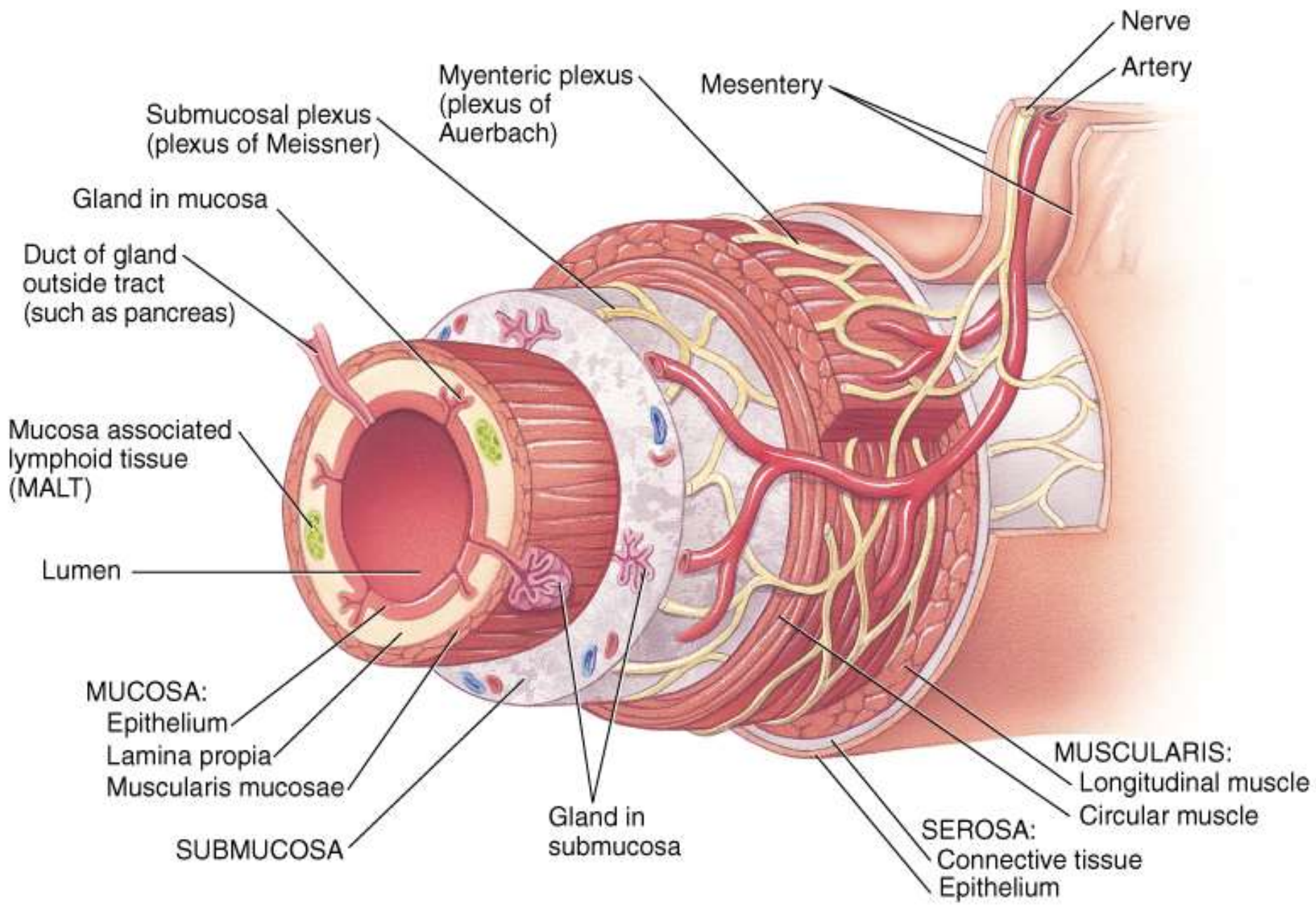
The Stomach

By :

Tehseen Anwar

Monday, June 02, 2014

03450743978



Tunica mucosa



- ❖ It is inner layer.
- ❖ Has extensive folds called gastric folds.
- ❖ Surface is covered by small invaginations called gastric pits.
- ❖ It is continuous with gastric glands.
- ❖ Mucous secretory products prevent digestion of mucosa.

Tunica mucosa



Epithelium simple columnar

- ❖ The surface epithelium of the stomach is made up of surface mucous cells.
- ❖ secretion protects the lining of the stomach from the acid produced by the gastric glands.
- ❖ The surface mucous cells have round or elongated nuclei and darker cytoplasm.

Continue..



- Rapid turnover rate 3 to 4 days.

This layer contains

- loose connective tissue
- lymphoid cells and occasional lymphoid nodules.
- The gastric glands are also located in this layer.

Tunica mucosa



Lamina propria

It has following contents

- ❖ Loose connective tissue
- ❖ Blood vessels
- ❖ Nerve vessels
- ❖ Lymphoid tissue called Galt or Malt
- ❖ Lymphatic vessels
- ❖ Collagen fibers

Continue..



- ❖ Stratum compactum is a layer of collagen and elastic fibers between the glands and the muscularis mucosae. It is often encountered in the carnivores.

Lamina Muscularis

- ❖ Relatively thick 2 to 3 layers of smooth muscles extended in between glands of lamina propria.

Tunica submucosa



In the dense connective tissue of the submucosa these cells present

- ❖ lymphoid cells
- ❖ blood vessels
- ❖ Lymphatic vessels

Tunica submucosa



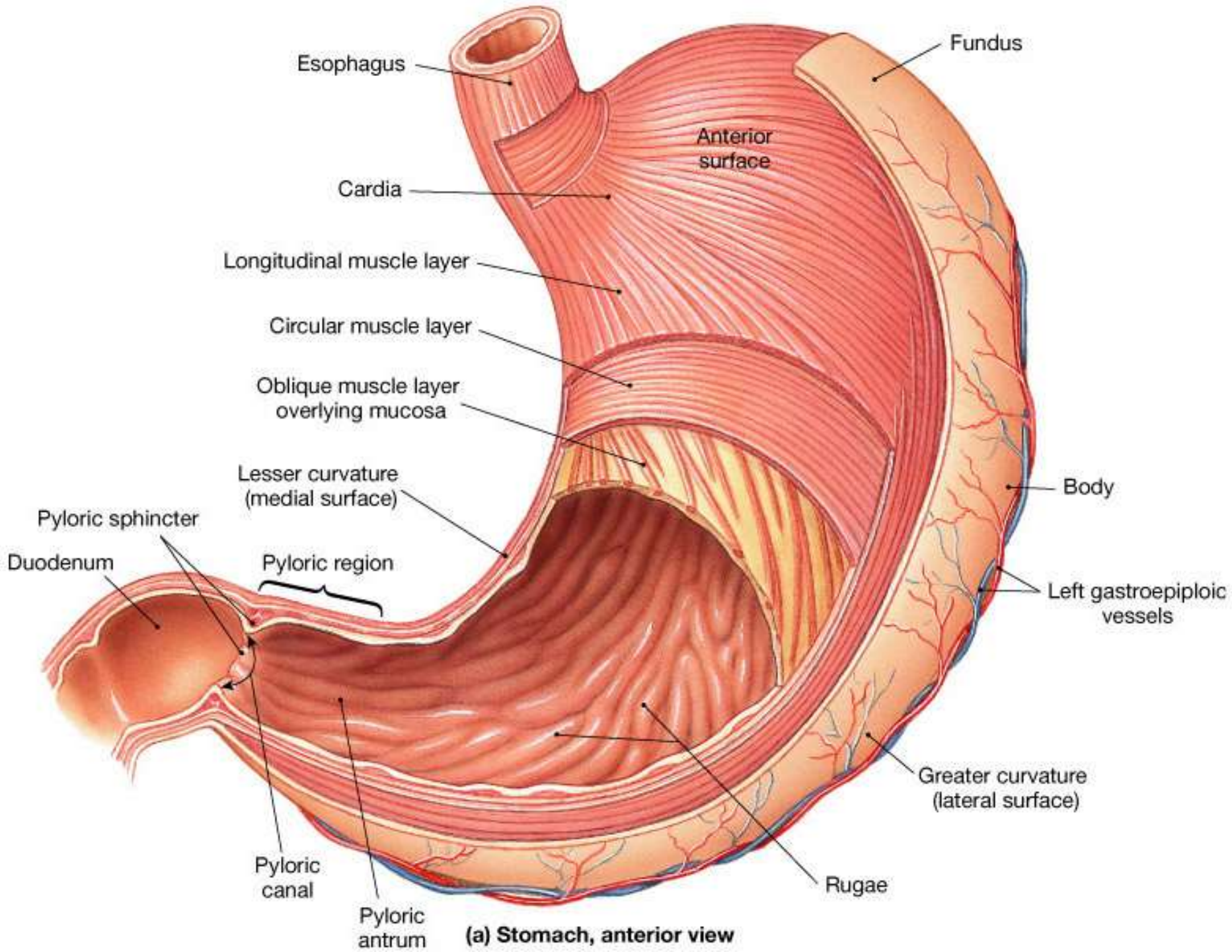
- ❖ Parasympathetic ganglia, known as submucosal/Meissners plexus, are found here.
- ❖ They along with sympathetic fibers are involved in the contraction of the smooth muscle cells.

Tunica muscularis



It has 3 layers and thickest in stomach

- outer longitudinal
- middle circular
- inner oblique
- ❖ The oblique layer is best developed in the cardia and body.
- ❖ The longitudinal layer is continuous with the longitudinal muscle layer of the esophagus and duodenum.



Tunica muscularis



- ❖ The inner circular muscle layer forms the cardiac sphincter.
- ❖ A distinctive muscular pyloric sphincter is also present between the pyloric stomach and the duodenum.
- ❖ This is called torus pyloricus in ruminant and pigs.

Tunica muscularis

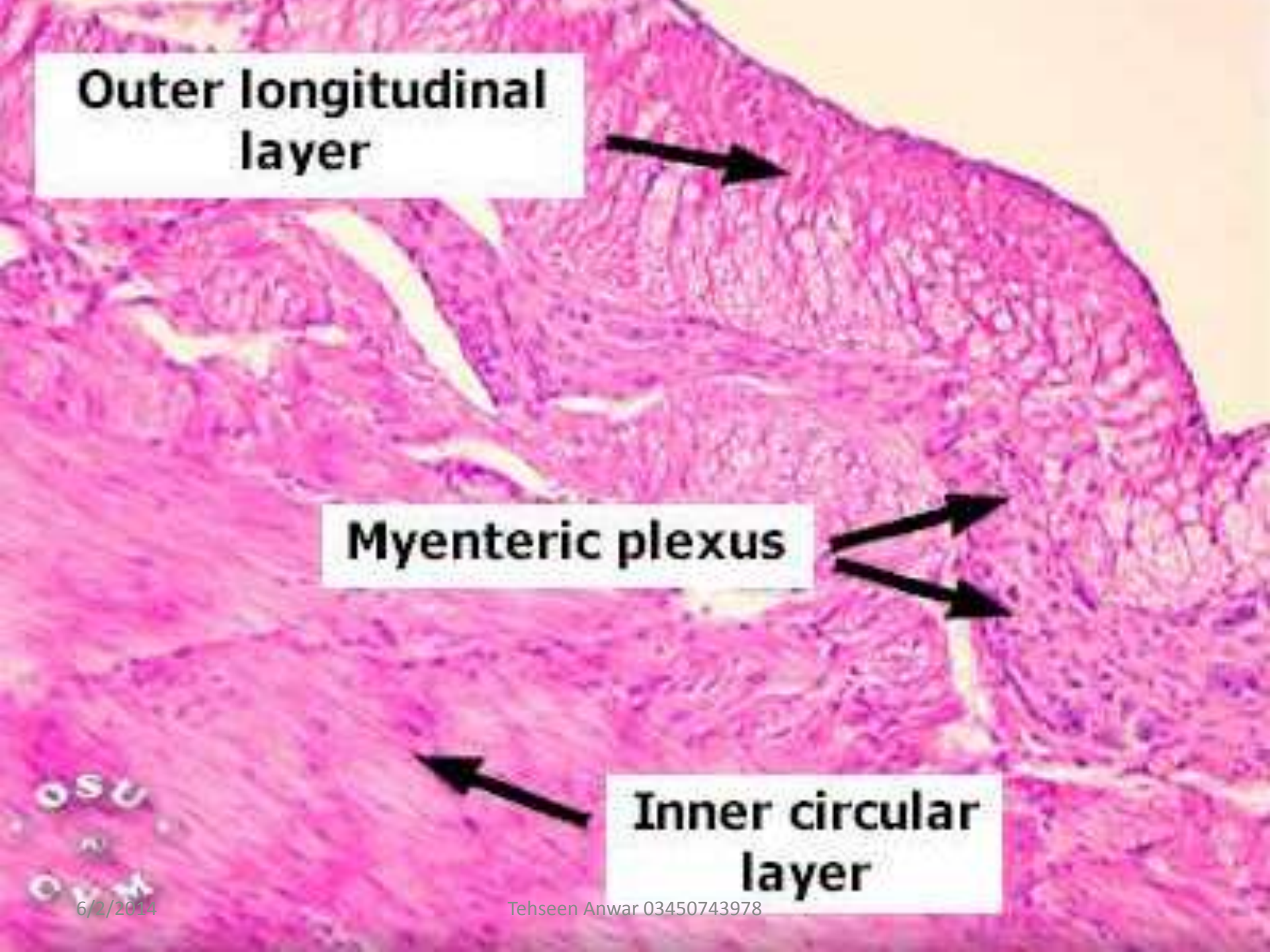


- ❖ Parasympathetic ganglia, known as the myenteric plexus (Auerbach's), are found between the layers central and outer of muscles.
- ❖ They are involved, along with sympathetic fibers, control of the contraction of the muscles.

Outer longitudinal layer

Myenteric plexus

Inner circular layer



Tunica serosa



❖ The outermost layer of the stomach is the tunica serosa (visceral peritoneum).

It contains

- ❖ loose connective tissue.
- ❖ blood vessels.
- ❖ covering is mesothelial cells.

Gastric glands



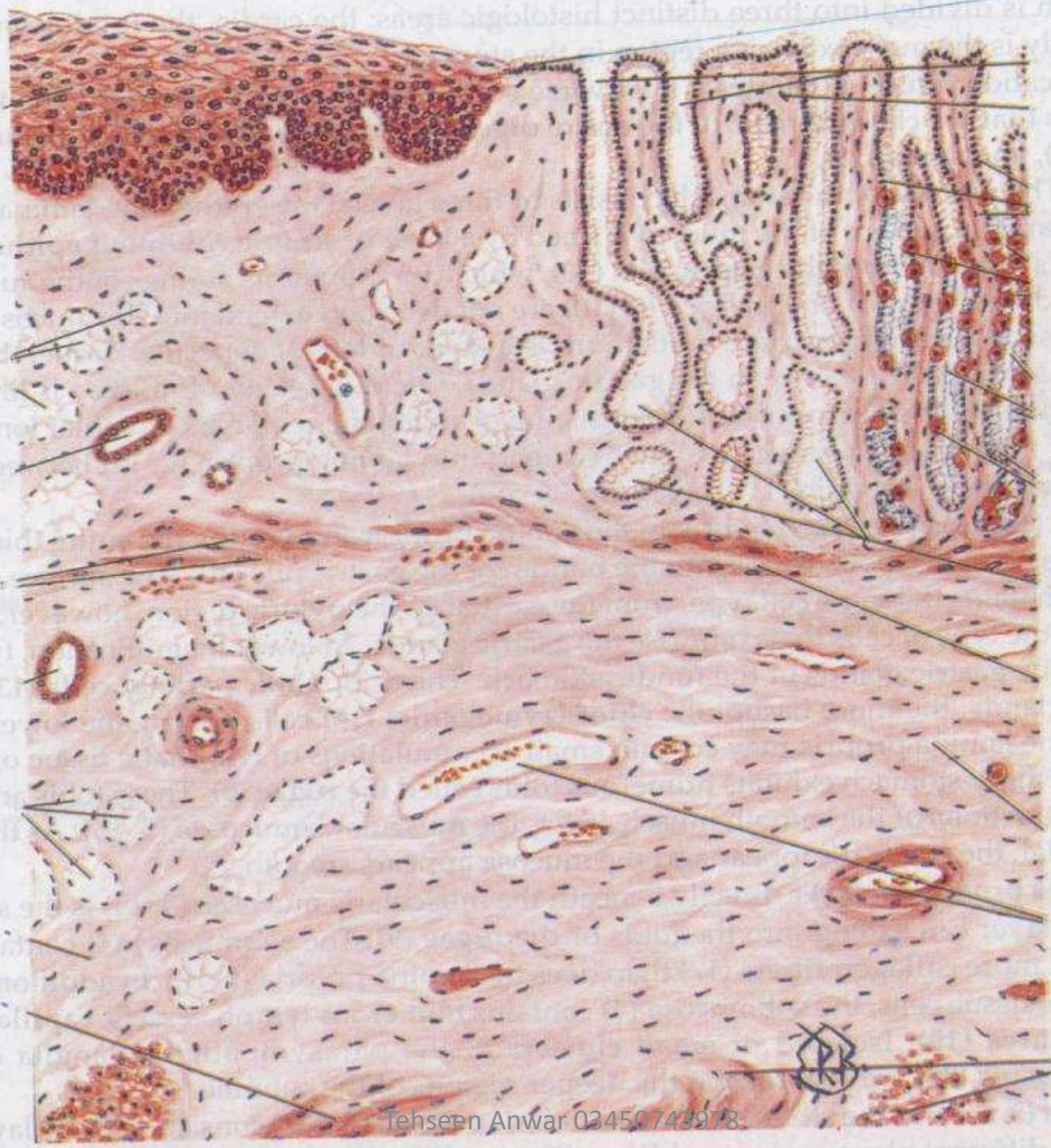
Cardiac glands

- ❖ Medium gastric pits.
- ❖ Short, Simple, branched, coiled tubular glands.
- ❖ cells are cuboidal and nuclei is basal in position.
- ❖ Parietal cells may occur at junction of cardiac and fundic gland region.

Esophagus

Stomach

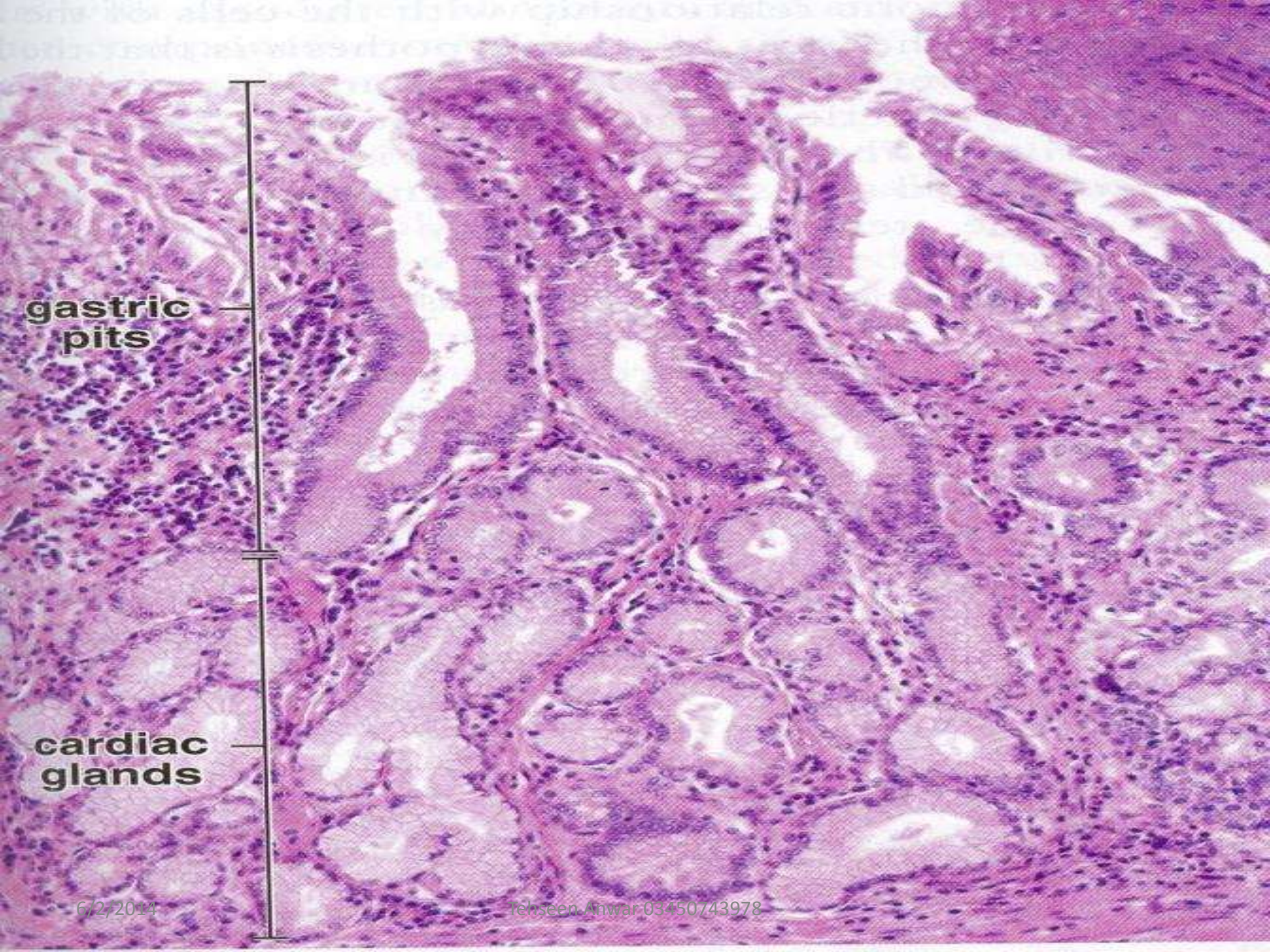
- 1 Stratified squamous epithelium
- 2 Lamina propria (esophagus)
- 3 Esophageal cardiac glands
- 4 Excretory duct
- 5 Muscularis mucosae (esophagus)
- 6 Excretory duct
- 7 Esophageal glands proper
- 8 Submucosa
- 9 Muscularis externa (esophagus)



- 10 Gastric epithelium
- 11 Gastric pits
- 12 Lamina propria (stomach)
- 13 Mucous neck cells
- 14 Parietal cells
- 15 Zymogenic (chief) cells
- 16 Gastric glands
- 17 Cardiac glands (stomach)
- 18 Muscularis mucosae (stomach)
- 19 Submucosa
- 20 Blood vessels (venule and arteriole)
- 21 Muscularis externa (stomach)

6/2/2014

Tehseen Anwar 03450743978



**gastric
pits**

**cardiac
glands**

Gastric glands



Fundic glands

- ❖ Smallest gastric pits
- ❖ Simple, branched, straight tubular glands extended to lamina muscularis.

It contain several cell types:

- Surface mucous cells.
- Mucus neck cells.
- Undifferentiated reserve cells.
- Chief cells or zymogen cells .

Fundic glands



- Parietal cells.
- Endocrine cells.
- ❑ **Surface mucous cells**
- ❖ Columnar cells with basally located oval nuclei,
Cover the surface and line the gastric pits.

Fundic glands



❑ Mucus neck cells

- ❖ Found at the neck of the gland. Smaller than surface mucous cells and contain less amount of mucin in the cytoplasm. Nucleus round. Secrete a soluble mucus.

❑ Undifferentiated reserve cells

- ❖ Located at the neck region. Through cell division give rise to
 - ❖ surface epithelial
 - ❖ glandular cells

Fundic glands



❑ Chief cells or zymogen cells

- ❖ Most numerous of gastric glands.
- ❖ Cuboidal with spherical nucleus near base of cell.
- ❖ Having zymogen granules between nucleus and free surface.
- ❖ basal area of cytoplasm have rER.

Fundic glands



- ❖ They secrete pepsinogen.
- ❖ Chief cells in the ruminant abomasum secrete renin. In some species the chief cells also secrete gastric intrinsic factor

Parietal cells

- ❖ These are large, triangular cells with acidophilic cytoplasm and central nuclei.
- ❖ Secrete HCL , gastric intrinsic factor

Fundic glands



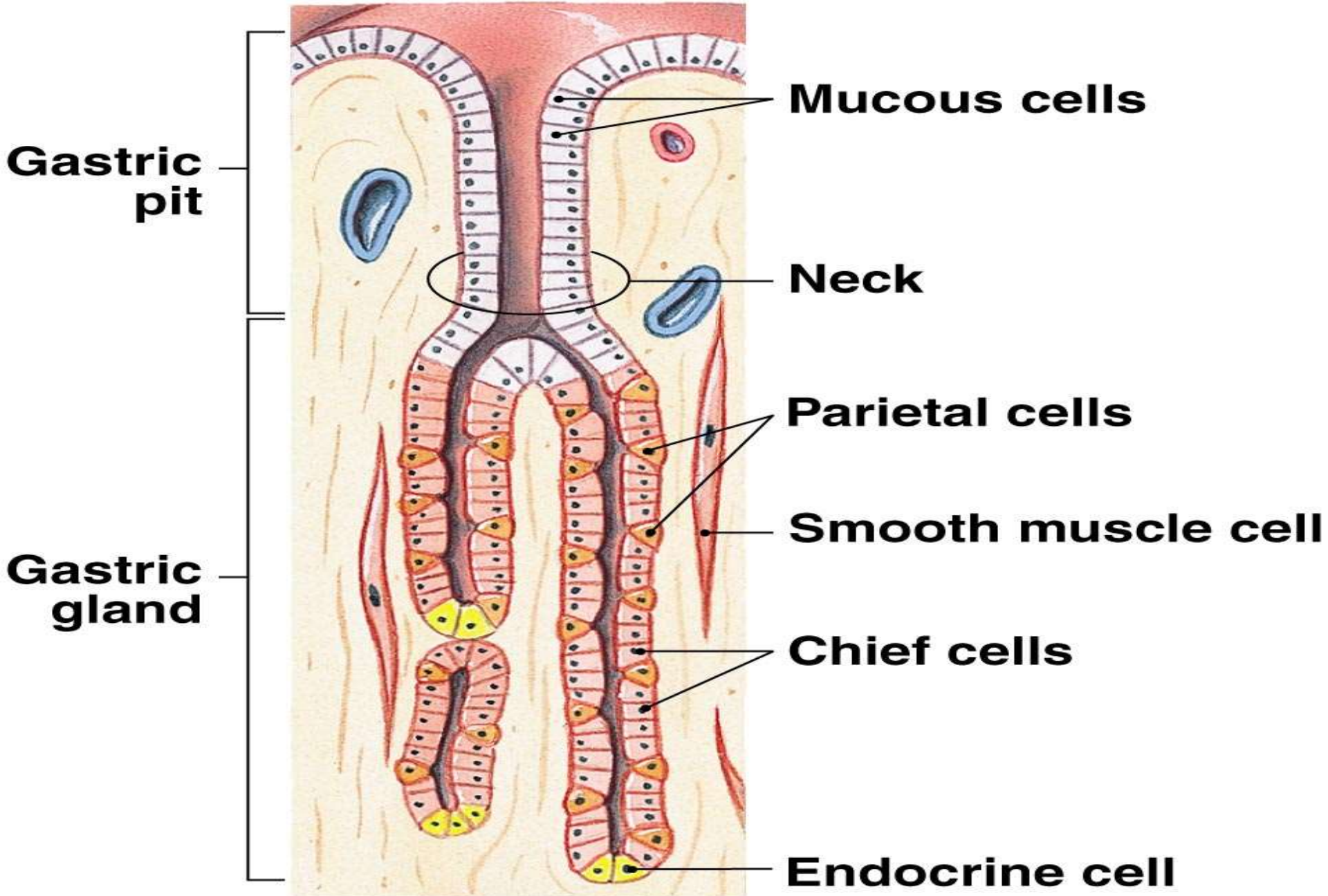
❑ Endocrine cells

- ❖ Mostly wedged between basement membrane and chief cells.
- ❖ 12 endocrine cell types identified by EM in GIT.
- ❖ All have numerous small membrane bounded granules, mostly at basal cytoplasm, relatively little rER and small Golgi complex.

Fundic glands



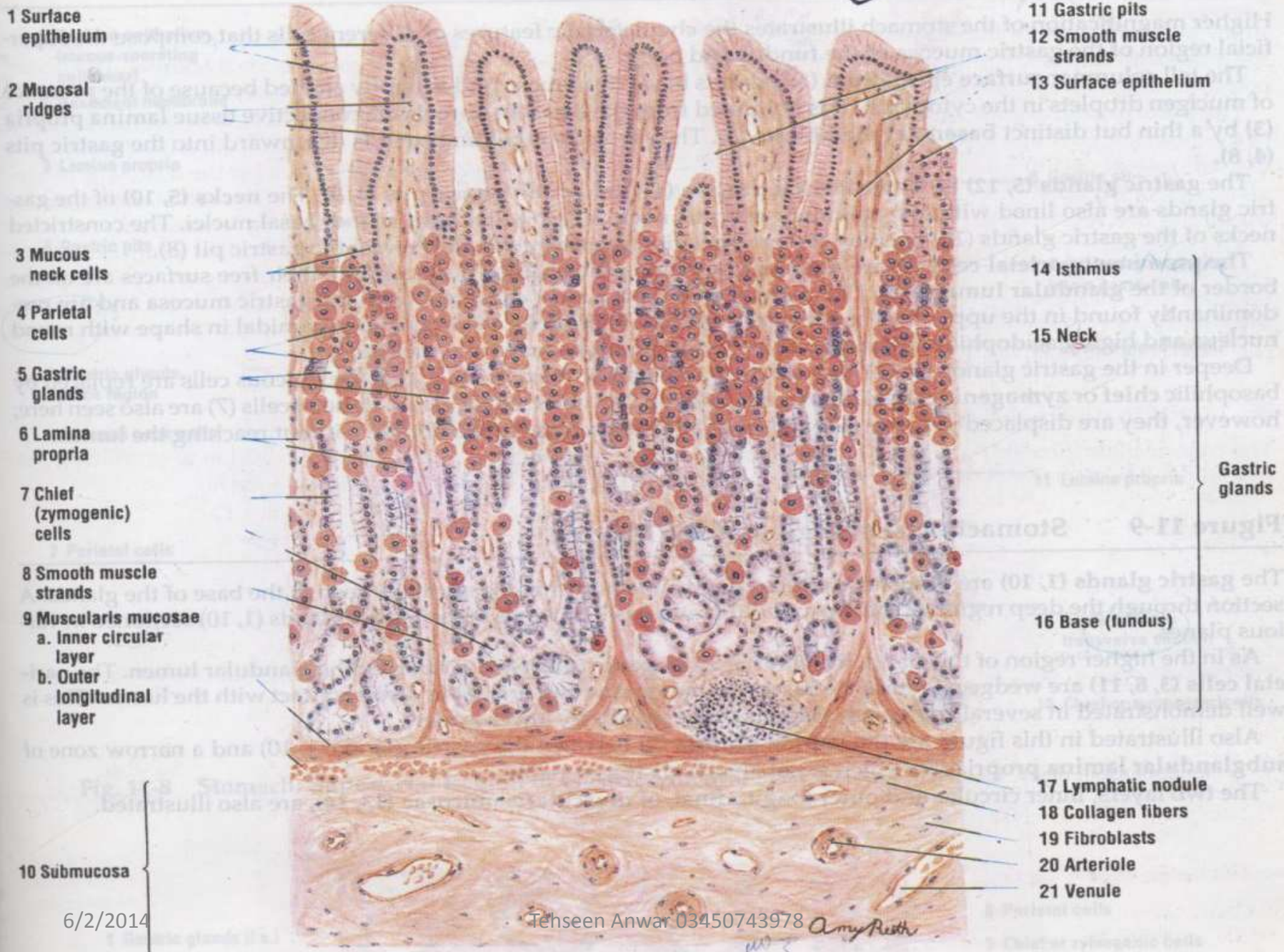
- Many of these cells visible with silver staining therefore also referred as argentaffin cells or argyrophilic cells.
- Some cells also demonstrated with potassium dichromate solution so referred as enterochromaffin cells.
- These cells secrete hormones gastrin, secretin, cholecystokinin and gastric inhibitory polypeptide.



(d)

6/2/2014

Tenseen Anwar 03450743978



- 1 Surface epithelium
- 2 Mucosal ridges
- 3 Mucous neck cells
- 4 Parietal cells
- 5 Gastric glands
- 6 Lamina propria
- 7 Chief (zymogenic) cells
- 8 Smooth muscle strands
- 9 Muscularis mucosae
 - a. Inner circular layer
 - b. Outer longitudinal layer
- 10 Submucosa

- 11 Gastric pits
- 12 Smooth muscle strands
- 13 Surface epithelium
- 14 Isthmus
- 15 Neck
- 16 Base (fundus)
- 17 Lymphatic nodule
- 18 Collagen fibers
- 19 Fibroblasts
- 20 Arteriole
- 21 Venule

Gastric glands

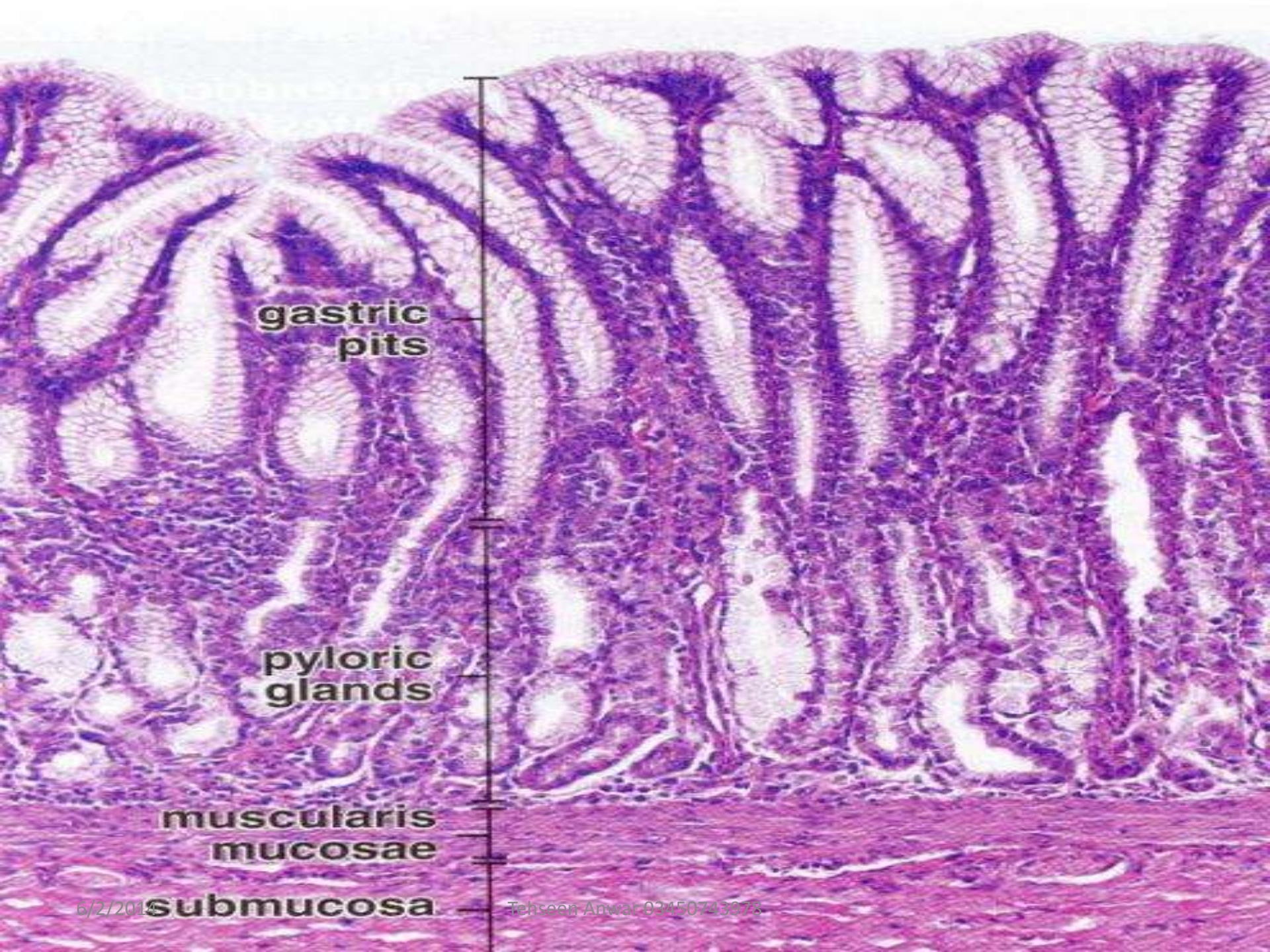
6/2/2014

Gastric glands



Pyloric glands

- ❖ Large and deepest gastric pits.
- ❖ Simple, branched, coiled tubular glands.
- ❖ Relatively short.
- ❖ Mucus secreting.
- ❖ Cells with flat nuclei at base lightly stained apical cytoplasm.



**gastric
pits**

**pyloric
glands**

**muscularis
mucosae**

submucosa

10 Epithelium (mucous columnar)
11 Epithelium (h.s.)

1 Lymphocyte migrating through the epithelium

2 Muscle fibers from the muscularis mucosae

3 Mucosal ridges

4 Gastric pits

5 Pyloric glands (l.s.)

6 Pyloric glands (t.s.)

7 Muscle fibers passing into lamina propria

8 Arteriole

9 Venule

12 Gastric pits

13 Lamina propria

14 Pyloric glands (simple branched)

15 Muscle fibers from muscularis mucosae

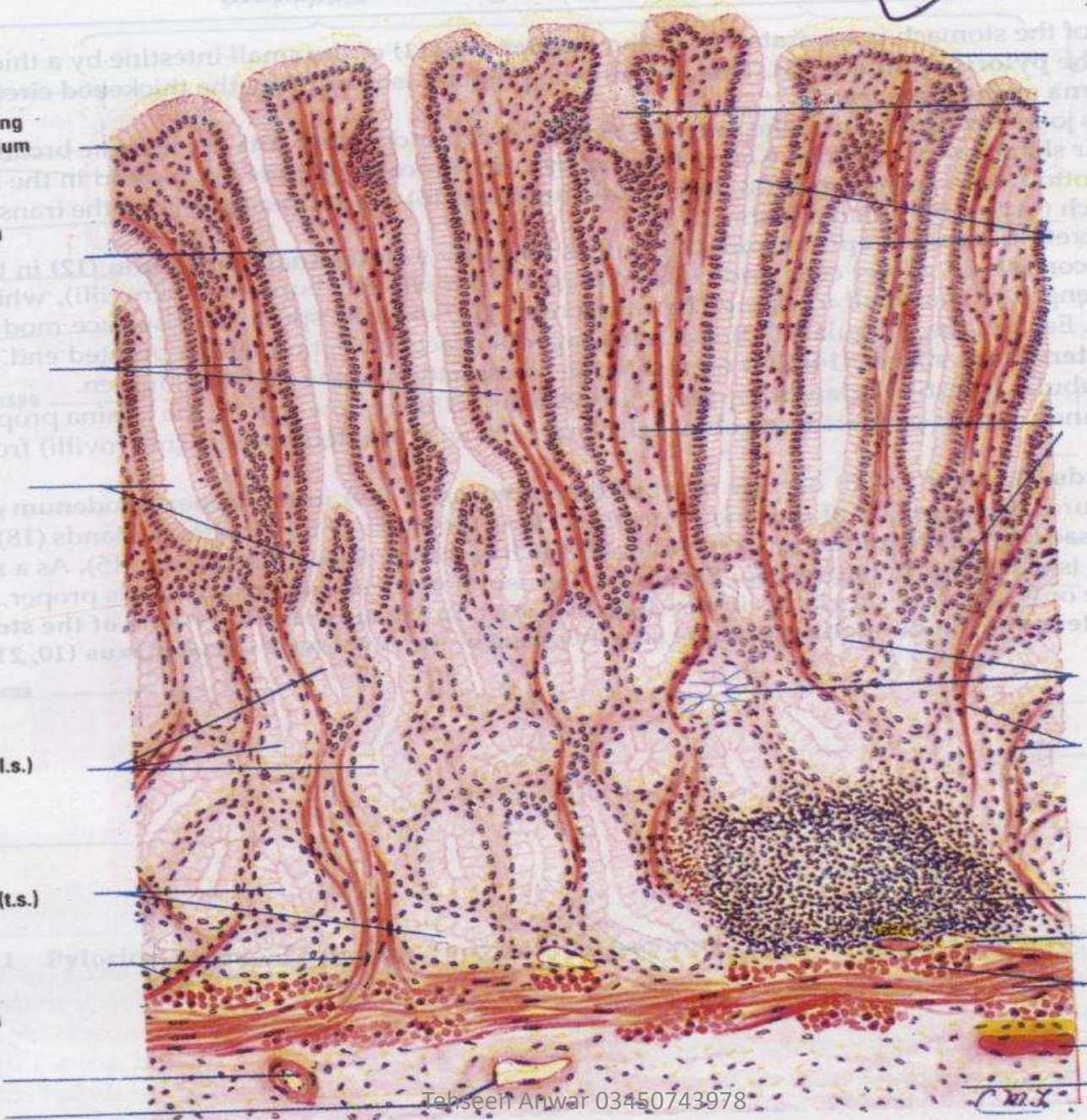
16 Lymphatic nodule

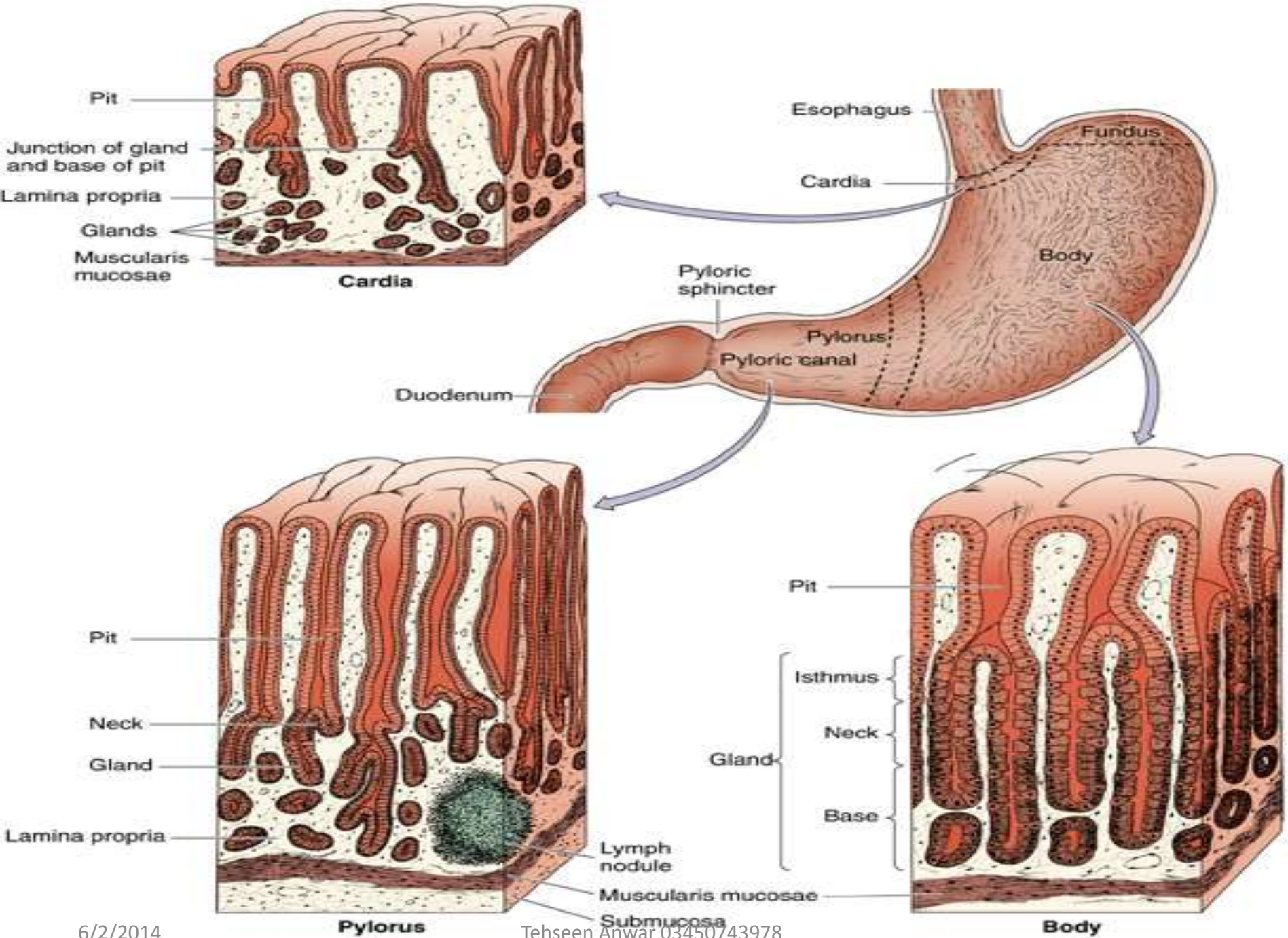
17 Capillary

18 Muscularis mucosae

19 Venule

20 Submucosa







Thank You